

KYPHOPLASTY FOR MANAGING COMPRESSION, PAIN, AND DIAGNOSTIC CONFIRMATION OF THORACOLUMBOSACRAL METASTASES FROM AXILLARY APOCRINE ADENOCARCINOMA: A CASE REPORT

Alfred Sutrisno Sim^{1*}, Herlina Uinarni², Edwin Destra³

Department of Neurosurgery, Faculty of Medicine, Tarumanagara University, Jakarta¹, Department of Anatomy, School of Medicine and Health Sciences, Atma Jaya Catholic University of Indonesia², Master Program in Biomedical Sciences, School of Medicine and Health Sciences, Atma Jaya Catholic University of Indonesia³

**Corresponding Author : afreds.sim@gmail.com*

ABSTRAK

Metastasis tulang belakang merupakan komplikasi umum pada keganasan lanjut, yang sering kali menyebabkan nyeri hebat dan ketidakstabilan struktural. Adenokarsinoma apokrin aksila jarang bermetastasis ke tulang belakang, sehingga perjalanan klinisnya kurang dipahami. Kyphoplasty, teknik pembesaran tulang belakang minimal invasif, menawarkan penghilangan nyeri yang cepat, stabilisasi struktural, dan konfirmasi diagnostik lesi metastasis. Seorang pria berusia 72 tahun dengan riwayat adenokarsinoma apokrin aksila kiri datang dengan nyeri punggung dan pinggang yang progresif. Pencitraan menunjukkan metastasis torakolumbosakral dengan stenosis kanal, dan histopatologi mengonfirmasi adenokarsinoma metastasis. Kyphoplasty dilakukan pada vertebra L2-L4 untuk mengatasi nyeri dan kompresi. Pascaprosedur, pasien melaporkan penghilangan nyeri yang signifikan, peningkatan mobilitas, dan tidak ada komplikasi. Prosedur ini juga memfasilitasi pengambilan sampel jaringan untuk konfirmasi diagnostik. Kyphoplasty secara efektif mengatasi nyeri, kompresi tulang belakang, dan tantangan diagnostik dalam kasus metastasis torakolumbosakral yang langka ini dari adenokarsinoma apokrin aksila. Laporan ini menekankan pentingnya kyphoplasty sebagai alat terapi dan diagnostik untuk penyakit tulang belakang metastasis dan menyoroti perlunya penelitian lebih lanjut tentang kemanjurannya dalam jangka panjang.

Kata kunci : adenokarsinoma apokrin aksila, kyphoplasty, laporan kasus, metastasis torakolumbosakral, metastasis tulang belakang

ABSTRACT

Spinal metastases are a common complication in advanced malignancies, often leading to significant pain and structural instability. Axillary apocrine adenocarcinoma rarely metastasizes to the spine, making its clinical course poorly understood. Kyphoplasty, a minimally invasive vertebral augmentation technique, offers rapid pain relief, structural stabilization, and diagnostic confirmation of metastatic lesions. A 72-year-old male with a history of left axillary apocrine adenocarcinoma presented with progressive back and lumbar pain. Imaging revealed thoracolumbosacral metastases with canal stenosis, and histopathology confirmed metastatic adenocarcinoma. Kyphoplasty was performed on vertebrae L2-L4 to manage pain and compression. Post-procedure, the patient reported significant pain relief, improved mobility, and no complications. The procedure also facilitated tissue sampling for diagnostic confirmation. Kyphoplasty effectively managed pain, spinal compression, and diagnostic challenges in this rare case of thoracolumbosacral metastases from axillary apocrine adenocarcinoma. This report emphasizes the importance of kyphoplasty as a therapeutic and diagnostic tool for metastatic spinal disease and highlights the need for further studies on its long-term efficacy.

Keywords : axillary apocrine adenocarcinoma, case report, kyphoplasty, spinal metastases, thoracolumbosacral metastases

INTRODUCTION

Spinal metastases are a common complication in advanced malignancies, often leading to significant pain, neurological impairment, and reduced quality of life. The vertebral column is a frequent site of metastatic spread due to its extensive venous network, facilitating hematogenous dissemination. Common primary malignancies associated with spinal metastases include breast, lung, prostate, and renal cancers, while metastases from axillary apocrine adenocarcinoma are exceptionally rare (Touimi SH, Nchiepo D, Mbarki I, Elkacemi H, Elmajjaoui S, Kebdani T, et al, 2020). Tumor invasion into the vertebrae disrupts bone homeostasis, causing osteolysis, pathological fractures, and spinal cord compression. These complications necessitate timely and effective interventions to alleviate pain, stabilize the spine, and evaluate disease progression. Conventional treatments, such as systemic therapy, radiotherapy, and surgical decompression, have limitations, particularly in patients with advanced disease and widespread metastases (Giammalva GR, Costanzo R, Paolini F, Benigno UE, Porzio M, Brunasso L, et al, 2022).

Kyphoplasty, a minimally invasive vertebral augmentation technique, has gained recognition as a valuable intervention for managing spinal metastases. The procedure involves percutaneous cement injection to restore vertebral height, reinforce structural integrity, and reduce micromovements that contribute to pain (Kővári B, Kocsis L, Varga E, 2018).

Kyphoplasty not only alleviates mechanical instability but also provides rapid pain relief compared to external beam radiotherapy, which often takes weeks to achieve its full effect. Moreover, it offers advantages over vertebroplasty, such as better height restoration and a lower risk of cement leakage. In metastatic bone disease, kyphoplasty has additional utility for diagnostic purposes, particularly in confirming the presence and extent of metastases when integrated with tissue sampling and imaging studies. This case report discusses a patient with axillary apocrine adenocarcinoma and thoracolumbosacral metastases who underwent kyphoplasty to address spinal compression, alleviate pain, and confirm metastatic involvement. The rarity of this metastatic pattern underscores the importance of recognizing atypical cancer dissemination. By detailing the clinical presentation, imaging findings, histopathological results, and therapeutic outcomes, this report emphasizes the role of kyphoplasty in managing metastatic spinal disease and contributes to the growing evidence supporting its utility as both a therapeutic and diagnostic tool.

CASE REPORT

A 72-year-old male experienced progressively worsening back and lumbar pain over several weeks. His medical history included left axillary apocrine adenocarcinoma, for which he underwent surgical resection in February 2023, followed by 30 cycles of radiotherapy and six cycles of immunotherapy (Ketruga 200 mg). Recent positron emission tomography-computed tomography (PET-CT) imaging indicated disease recurrence with suspected metastases, necessitating further evaluation. Contrast-enhanced magnetic resonance imaging (MRI) of the thoracolumbar spine identified multiple hypointense lesions with contrast enhancement affecting the vertebral bodies of T9, T10, T11, T12, L1, L3, L4, S1, and S3, consistent with metastatic involvement. At L2-L3, bilateral subforaminal bulging led to moderate lateral recess stenosis, while L3-L4 exhibited similar findings with increased severity and mild foraminal stenosis. L4-L5 demonstrated bilateral subforaminal extrusion, causing severe lateral recess stenosis and mild foraminal stenosis, whereas L5-S1 showed extrusion contributing to mild spinal canal and foraminal stenosis, with predominant left-sided lateral recess narrowing. Mild facet joint fluid accumulation was observed at L4-L5, indicating degenerative changes.

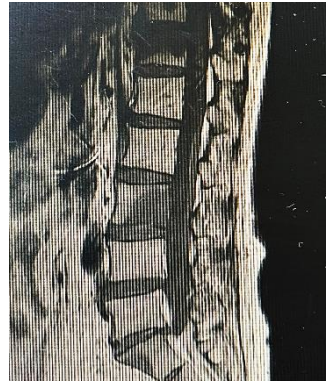

Figure 1. Pre-Kyphoplasty Sagittal MRI Of The Lumbar Spine Showing Vertebral Compression Fractures At L2-L4 With Metastatic Involvement and Spinal Canal Narrowing

Histopathological analysis of biopsied tissue confirmed thoracolumbosacral metastases originating from left axillary apocrine adenocarcinoma, with predominant involvement of thoracic vertebrae 9 and 12 and lumbar vertebra 3. The primary tumor origin remained uncertain but was suspected to be the previously diagnosed axillary carcinoma. The patient received multimodal management, including pain control, hepatic nodule evaluation, and spinal bracing to reduce mechanical strain. Additional therapy included palliative radiotherapy and intravenous zoledronic acid (Zometa) to mitigate osteolytic activity associated with metastatic bone disease.

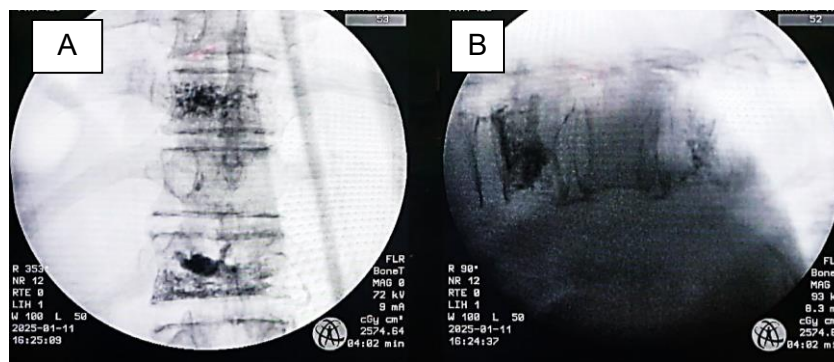


Figure 2. (A) Post-Kyphoplasty Fluoroscopic Image (Anteroposterior View) Showing Vertebral Stabilization with PMMA Cement Augmentation. (B) Post-Kyphoplasty Fluoroscopic Image (Lateral View) Demonstrating Partial Vertebral Height Restoration and Improved Spinal Alignment

Table 1. Timeline of Clinical Events and Interventions in a Patient with Thoracolumbosacral Metastases from Axillary Apocrine Adenocarcinoma

Date	Clinical Event
Feb 2023	Axillary adenocarcinoma surgery
Mar-Jun 2023	Radiotherapy (30 cycles) and immunotherapy (six cycles)
Dec 2024	PET-CT: recurrent disease with suspected spinal metastases
26 Dec 2024	MRI: multiple vertebral metastases, canal stenosis
27 Dec 2024	Biopsy confirmed metastatic adenocarcinoma
28 Dec 2024	Pain management initiated, kyphoplasty planned
Jan 2025	Kyphoplasty on L2-L4 performed
Post-procedure	Pain relief, improved mobility

Given the severity of vertebral involvement, kyphoplasty was performed at L2-L4 to alleviate pain and restore vertebral stability. Post-procedure MRI demonstrated partial vertebral height restoration at treated levels with hyperintense signal changes at the cement augmentation sites, reflecting polymethyl methacrylate (PMMA) deposition. Edema surrounding the metastatic lesions appeared reduced, suggesting stabilization of the vertebral

structures. Neural compression, particularly at the lateral recesses, showed improvement, correlating with alleviation of stenosis-related symptoms. No new pathological fractures or post-procedural complications were detected. The findings confirmed successful vertebral stabilization and biomechanical improvement, aligning with the patient's reported reduction in pain intensity and improved mobility following the intervention. Post-procedure assessment demonstrated significant pain reduction, as measured by the Visual Analog Scale (VAS), along with improved mobility and no immediate post-procedural complications.

DISCUSSION

Spinal metastases are a frequent complication in advanced malignancies; however, metastasis from axillary apocrine adenocarcinoma to the thoracolumbosacral region is extremely rare. Hematogenous and lymphatic dissemination are the primary mechanisms by which tumor cells spread from the axillary region to distant skeletal structures. Once metastases infiltrate the vertebrae, they disrupt normal bone remodeling by inducing osteoclastic activity, leading to structural weakening, pain, and an elevated risk of vertebral compression fractures (Sciubba DM, Yurter A, Ju DG, Gokaslan ZL, Fisher CG, Rhines LD, et al, 2015). In this case, the extensive vertebral involvement, characterized by multiple levels of stenosis and osteolysis, caused progressive back pain and functional impairment, necessitating intervention beyond conventional pain management. The presence of metastases in the vertebrae also increases the risk of spinal cord compression, which can significantly impact neurological function and overall prognosis (Yamada Y, Toribatake Y, Okamoto S, Kato S, Kobayashi M, Tsuchiya H, 2023).

Kyphoplasty has proven to be an effective intervention for managing pain, stabilizing vertebral structures, and addressing diagnostic uncertainties in patients with metastatic spinal disease. The procedure involves injecting polymethylmethacrylate (PMMA) cement into collapsed vertebrae, which restores height and reinforces structural integrity, thereby reducing micromovements that contribute to mechanical pain (Hopkins T, Eggington S, Quinn M, Ricker CN, 2020). Kyphoplasty also provides immediate structural support to prevent further vertebral collapse and reduces the risk of progressive deformity. In this case, the use of kyphoplasty not only provided rapid pain relief, as evidenced by improved Visual Analog Scale (VAS) scores, but also facilitated diagnostic confirmation of metastases through biopsy. The minimally invasive nature of kyphoplasty, with its low complication rates compared to open surgical decompression, further supports its role as a preferred intervention in fragile oncologic patients (Wang C, Chen W, Yan SL, Guo K, Feng S, 2021).

Compared to other therapeutic options, kyphoplasty offers several advantages. It provides faster pain relief than external beam radiotherapy, which may require weeks for maximal efficacy. Unlike systemic therapies, such as bisphosphonates and radiotherapy, which target tumor progression and osteolytic activity, kyphoplasty directly addresses mechanical instability while also serving a diagnostic purpose in evaluating metastatic involvement (Lü X, Jiang Y, Zhu Z, Lv X, Wu J, Huang J, et al, 2020). Compared to vertebroplasty, kyphoplasty allows for controlled cement deposition, reducing the risk of cement leakage and associated neurological complications. However, kyphoplasty does not address the underlying tumor burden or disease progression, necessitating adjunctive therapies such as systemic treatment and localized radiotherapy (Lotan R, Haimovich Y, Schorr L, Goldstein A, Hershkovich O, 2022). The long-term efficacy of kyphoplasty in metastatic spinal disease remains uncertain, particularly with the potential for further vertebral involvement and adjacent level fractures. Through this case, kyphoplasty demonstrated its utility in addressing spinal compression, alleviating pain, and confirming metastatic spread in a rare oncologic scenario.

CONCLUSION

This case highlights the successful use of kyphoplasty in managing thoracolumbosacral metastases from axillary apocrine adenocarcinoma, an exceptionally rare metastatic pattern. Pre-procedure magnetic resonance imaging demonstrated vertebral compression fractures at the second, third, and fourth lumbar vertebrae with metastatic involvement, leading to spinal instability and significant pain. Post-kyphoplasty imaging confirmed successful vertebral height restoration, stabilization of the affected levels, and proper polymethyl methacrylate cement augmentation, with reduced edema and alleviation of neural compression. The procedure not only stabilized the spine but also facilitated diagnostic confirmation of metastatic involvement through biopsy. Kyphoplasty demonstrated its utility as a minimally invasive intervention offering rapid clinical improvement in pain and functional outcomes with minimal complications. This report underscores the importance of recognizing atypical metastatic patterns and integrating kyphoplasty into the comprehensive management of metastatic spinal disease.

ACKNOWLEDGMENT

The researcher would like to express his gratitude for the support, inspiration and assistance to all parties in helping the researcher complete this research, including the participants who were willing to participate in the research until it was completed.

REFERENCES

- Agrawal R, Garg C, Agarwal A, Kumar P. (2015). *Axillary Apocrine Adenocarcinoma in a Young Male Suspected Initially on Fine-Needle Aspiration Cytology*. *J Cytol. Appl Sci.*Kővári B, Kocsis L, Varga E. (2018). *Expression of Growth Hormone-Releasing Hormone Receptors in Apocrine Adnexal Tumours and Apocrine Glands of the Skin*. *Polish J Pathol*.
- Giammalva GR, Costanzo R, Paolini F, Benigno UE, Porzio M, Brunasso L, et al. (2022). *Management of Spinal Bone Metastases With Radiofrequency Ablation, Vertebral Reinforcement and Transpedicular Fixation: A Retrospective Single-Center Case Series*. *Front Oncol*.
- He S, Zhang Y, Lv N, Wang S, Wang Y, Wu S, et al. (2019). *The Effect of Bone Cement Distribution on Clinical Efficacy After Percutaneous Kyphoplasty for Osteoporotic Vertebral Compression Fractures*. *Medicine (Baltimore)*.
- Hopkins T, Eggington S, Quinn M, Ricker CN. (2020) *Cost-Effectiveness of Balloon Kyphoplasty and Vertebroplasty Versus Conservative Medical Management in the USA*. *Osteoporos Int*.
- Izumida T, Sangen R, Usuda D, Kasamaki Y. (2021). *Successful Treatment With Percutaneous Balloon Kyphoplasty for Syndrome of Inappropriate Secretion of Antidiuretic Hormone Associated With Vertebral Compression Fracture: A Case Report*. *Am J Case Rep*.
- Liao J, Chen MJW, Lin TY, Chen WP. (2021). *Biomechanical Comparison of Vertebroplasty, Kyphoplasty, Vertebrae Stent for Osteoporotic Vertebral Compression Fractures—A Finite Element Analysis*.
- Li D, Zhou Y, Cui H, Kong L, Zhu W, Chai X, et al. (2021). *Analysis of the Curative Effect of Percutaneous Kyphoplasty in the Treatment of Osteoporotic Vertebral Compression Fracture With Intravertebral Clefts*. *Medicine (Baltimore)*.
- Lü X, Jiang Y, Zhu Z, Lv X, Wu J, Huang J, et al. (2020). *Changes of the Adjacent Discs and*

Vertebrae in Patients With Osteoporotic Vertebral Compression Fractures Treated With or Without Bone Cement Augmentation. Spine J.

- Lotan R, Haimovich Y, Schorr L, Goldstein A, Hershkovich O. (2022). *Double-Balloon Kyphoplasty Results in Better Radiographic Outcomes Than a Single-Balloon Kyphoplasty in Treating Osteoporotic Spinal Fractures. J Clin Med.*
- Madassery S. (2020). *Vertebral Compression Fractures: Evaluation and Management. Semin Intervent Radiol.*
- Mattie R, Brar N, Tram J, McCormick ZL, Beall DP, Fox AM, et al. (2021). *Vertebral Augmentation of Cancer-Related Spinal Compression Fractures. Spine (Phila Pa 1976).*
- Meyer C, Gaalen K van, Leschinger T, Scheyerer MJ, Neiss WF, Staat M, et al. (2019). *Kyphoplasty of Osteoporotic Fractured Vertebrae: A Finite Element Analysis About Two Types of Cement. Biomed Res Int.*
- Mishra PK, Dwivedi R, Dhillon CS. (2020). *Osteoporotic Vertebral Compression Fracture and Single Balloon Extrapedicular Kyphoplasty: Findings and Technical Considerations. Bull Emerg Trauma.*
- Nowikiewicz T, Głowacka-Mrotek I, Tarkowska M, Nowikiewicz M, Zegarski W. (2020). *Failure of Sentinel Lymph Node Mapping in Breast Cancer Patients Qualified for Treatment Sparing Axillary Lymph Nodes—Clinical Importance and Management Strategy—One-center Analysis. Breast J.*
- O'Neill BE. (2023). *Utilization of Vertebroplasty/Kyphoplasty in the Management of Compression Fractures: National Trends and Predictors of Vertebroplasty/Kyphoplasty. Neurospine.*
- R RFT, Hashizume J, Ikeda M, Hanaoka K, Kuniyasu H. (2018). *Axillary Carcinoma With Apocrine Differentiation: A Case Report. Clin Diagnostic Pathol.*
- Sciubba DM, Yurter A, Ju DG, Gokaslan ZL, Fisher CG, Rhines LD, et al. (2015). *A Systematic Review of Clinical Outcomes and Prognostic Factors for Patients Undergoing Surgery for Spinal Metastases Secondary to Breast Cancer. Glob Spine J.*
- Shaker H, Mahate Z, Dabritz G, Absar M. (2020). *Axillary Clearance Following Positive Sentinel Lymph Node Biopsy in Symptomatic Breast Cancer. In Vivo (Brooklyn).*
- Touimi SH, Nchiepo D, Mbarki I, Elkacemi H, Elmajjaoui S, Kebdani T, et al. (2020). *Apocrine Carcinoma of Breast in a Male Patient: Case Report. Tumori J.*
- Tsuruta S. (2024). *A Review of Cutaneous Apocrine Carcinoma: Epidemiology, Diagnosis, Prognosis, and Treatment Options. Jpn J Clin Oncol.*
- Uzunoglu I, Gurkan G, Cingöz İD, Atar M, Kaya I, Hancıoğlu S, et al. (2020). *Evaluation of Biopsy Results in Vertebra Compression Fractures Treated by Kyphoplasty. Ann Med Res.*
- Wang C, Chen W, Yan SL, Guo K, Feng S. (2021). *Comparison of Percutaneous Curved Kyphoplasty and Bilateral Percutaneous Kyphoplasty in Osteoporotic Vertebral Compression Fractures: A Randomized Controlled Trial. BMC Musculoskelet Disord.*
- Wyatt J, Powell S, Ahmed S, James A, Altaf K, Ahmed S, et al. (2023). *Inguinal Lymph Node Metastases From Rectal Adenocarcinoma: A Systematic Review. Tech Coloproctol.*
- Yamada Y, Toribatake Y, Okamoto S, Kato S, Kobayashi M, Tsuchiya H. (2023). *Recompression of Augmented Vertebrae After Balloon Kyphoplasty Is a Risk of Adjacent Vertebral Fracture. Spine Surg Relat Res.*